

EXHIBIT 8

STATE OF ILLINOIS)
) SS
COUNTY OF DUPAGE)

Affidavit of Daniel L. Sacco

1. For almost 25 years me and my wife, Mary, have lived at 400 Cliff Court in Lisle, Illinois.
2. It was at our home on Cliff Court where we raised our five children: Jacqueline, Angela, Marissa, Arthur and Antionette.
3. It was also at our home on Cliff Court where I bathed, drank, cooked and showered in TCE contaminated water. Because of this, I contracted renal cell carcinoma that ultimately resulted in the removal of half of my right kidney. I submit this affidavit in support of my Level I Kidney Cancer Claim.
4. My name is Daniel L. Sacco. I am 57 years old. I was born on November 25, 1947.
5. After purchasing our home from Mr. and Mrs. Michael Mulick in September 1980, me and my wife, Mary, and -- at that time -- our three children, Jacqueline, Angela and Marissa, moved into 400 Cliff Court in Lisle, Illinois. A copy of the deed to our home is attached as Exhibit A. 400 Cliff Court is located in what the Met-Coil Systems Corporation TCE PI Trust Distribution Procedures refer to as "the Mejdrech Class Action Area."
6. Until August 2004, our home was served by a private well. A copy of the DuPage County Health Department Well Sealing Form is attached as Exhibit B.
7. Before it was sealed, the Illinois Environmental Protection Agency took a water sample from our well.
8. On February 26, 2001, the Illinois Department of Public Health reported the results of the IEPA sampling. A copy of the test results is attached as Exhibit C.
9. 1.12 ppb TCE was detected at our home. The IDPH told me that 1.12 ppb would not be expected to cause adverse health effects. This was reassuring to me and my wife at the time because only 5 months before I received my test results I was diagnosed with kidney cancer.
10. The IDPH also told me that I did not need to change any of my water usage habits based on the concentration of TCE in my water.

11. Ken Runkle from the Toxicology Section of IDPH communicated this information to me in the letter that enclosed my test results. A copy of that letter was also mailed to IEPA, IDPH West Chicago Regional Office and DuPage County Health Department.
12. After reading Mr. Runkle's letter, I believed that my water was safe and that IDPH in Springfield, IEPA, IDPH in West Chicago and DuPage County Health Department shared this belief.
13. Prior to Mr. Runkle's February 26th letter, I did not know there was any TCE in my well. This was the first time I discovered that I had been exposed to TCE.
14. Neither before nor because of Mr. Runkle's letter did I believe that my kidney cancer was caused by exposure to TCE. It was not until I spoke with my doctor, Steven Campbell, M.D., in 2004 about an article he was researching and going to write on kidney cancer that I first associated exposure to TCE and my renal cell carcinoma.
15. I was diagnosed with kidney cancer (renal cell carcinoma) on September 7, 2000. After complaining to my doctor about abdominal pain, a CT scan was ordered that revealed a 4 cm mass on my right kidney. Once the mass was determined to be cancerous, Dr. Campbell removed half of my right kidney. This history is detailed in a Discharge Summary from my hospitalization at Northwestern Memorial Hospital, attached as Exhibit D.
16. The Surgical Pathology Report confirmed my cancer was renal cell carcinoma, clear cell type, Fuhrman Grade II. A copy of the pathology report is attached as Exhibit E.
17. This was not my first bout with cancer. When I was 28 years old I was diagnosed with Kidney Cancer. My left kidney was removed at that time as a result.
18. When I was diagnosed with cancer again in September 2000 I assumed it was a relapse of my prior cancer. I later learned that my assumption was incorrect. At an appointment with Dr. Campbell in 2004, we discussed potential causes of my kidney cancer. At that appointment, Dr. Campbell told me it was basically unheard of and statistically improbable that a relapse would occur after 24 years of remission. I have no family history of kidney cancer, so I questioned what else could have been the cause. It was then that we discussed the TCE contamination in my neighborhood. Although Dr. Campbell did not tell me that TCE caused my renal cell carcinoma, he stated that it could have and that there was some scientific evidence of a link between TCE and kidney cancer. This was the first time I thought my kidney cancer was even associated with exposure to TCE.
19. Now, I have half a kidney left. I know if something else happens, I may end up on dialysis or, hopefully, eligible for a transplant. In either event, I appreciate how compromised my health really is. Although I try not to let this get me down, I am concerned about being there to take care of my family. Me and my wife have five

children. Currently, four of them plus Marissa's husband Craig (who is currently unemployed) are living with us at home.

20. I am concerned about what will happen to my family if kidney failure prevents me from working. Although my wife Mary works, my family is dependent on my income.

21. Dr. Campbell has told me that I have shown good progress and that my kidney function is good enough now to stay off dialysis. But, I know I am more susceptible to disease because of what my cancer has caused -- the removal of one-and-a-half kidneys and consequently, limited kidney function. My life expectancy, too, is also shortened, but I do not dwell on that. I am very active. I exercise 3-4 times a week. I am on an extremely restrictive diet. I do whatever I can to stay fit. Everything else about my kidney function and long term outlook I leave in Dr. Campbell's able hands.

FURTHER AFFIANT SAYETH NOT.

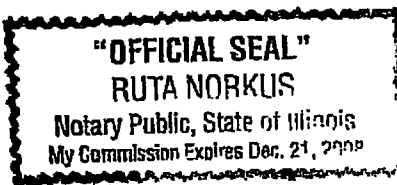
Daniel L. Sacco

Daniel L. Sacco

SUBSCRIBED AND SWORN TO
before me this 30th day of
March, 2005

Ruta Norkus

Notary Public



R80 - 66315

1980 OCT 27 PM 3:15

WARRANTY DEED

Joint Tenancy Illinois Statutory

(Individual to Individual)

(The Above Space For Recorder's Use Only)

George E. Cole

THE GRANTOR, MICHAEL S. MULICK and STEPHAN S. MULICK, his wife,

of the Village of Lisle County of DuPage State of Illinois
for and in consideration of Ten and No/100 DOLLARS.

CONVEY and WARRANT to DANIEL L. SACCO and MARY G. SACCO, his wife, of 5717 S. Washington St., (NAMES AND ADDRESS OF GRANTEEES)
of the Village of Hinsdale, DuPage County, Illinois

not in Tenancy in Common, but in JOINT TENANCY, the following described Real Estate situated in the County of DuPage in the State of Illinois, to wit:

Lot 2 in Woodridge Estates Unit Two, being a Subdivision of part of the South half of Section 14, Township 38 North, Range 10, East of the Third Principal Meridian, according to the Plat thereof recorded April 17, 1957 as Document 839233 and Certificates of Correction filed June 10, 1957 as Document 845130 and June 12, 1957 as Document 845568, in DuPage County, Illinois.

SUBJECT TO: Taxes for the year 1980 and subsequent years; Covenants and restrictions of record.

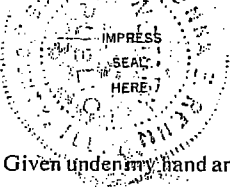hereby releasing and waiving all rights under and by virtue of the Homestead Exemption Laws of the State of Illinois. TO HAVE AND TO HOLD said premises not in tenancy in common, but in joint tenancy forever.

DATED this 25th day of September 19 80

Michael S. Mulick (Seal) *Stephan S. Mulick* (Seal)
MICHAEL S. MULICK STEPHAN F. MULICK

PLEASE PRINT OR TYPE NAME(S) BELOW SIGNATURE(S)

State of Illinois, County of DuPage ss. I, the undersigned, a Notary Public in and for said County, in the State aforesaid, DO HEREBY CERTIFY that MICHAEL S. MULICK and STEPHAN F. MULICK, his wife,



personally known to me to be the same persons whose names are subscribed to the foregoing instrument, appeared before me this day in person, and acknowledged that they signed, sealed and delivered the said instrument as their free and voluntary act, for the uses and purposes therein set forth, including the release and waiver of the right of homestead.

Given under my hand and official seal, this 16th day of October 19 80

Commission expires March 7 19 82 *Donna E. Renn* NOTARY PUBLIC

This instrument was prepared by 4756 Main St., Lisle, IL 60532 (NAME AND ADDRESS)

FOR REVENUE STAMPS HERE
COUNTY OF DU PAGE
REAL ESTATE TRANSFER TAX
No. 022 Page 1
1.00

STATE OF ILLINOIS
REAL ESTATE TRANSFER TAX
DEPT. OF REVENUE
53.00

00009
300000
300000

80 - 08 - 379 1106
5
CHANGE DUPAGE CO. DIVISION

ST. PAUL FEDERAL SAVINGS

6700 West North Avenue
Chicago, Illinois 60635
(City, State and Zip)

ADDRESS OF PROPERTY:
400 Cliff Court

Lisle, IL 60532
THE ABOVE ADDRESS IS FOR STATISTICAL PURPOSES ONLY AND IS NOT A PART OF THIS DEED.

SEND SUBSEQUENT TAX BILLS TO:
(Name)

DOCUMENT NUMBER

1510/347

U.S. FIVE YEAR FEDERAL SAVINGS
CERTIFICATE OF DEPOSIT

R 80 - 66315

WILLIAM D. DODD
JOINT TENANCY
INDIVIDUAL TO INDIVIDUAL

TO

Form # 2013 39-8

Handwritten signature

GEORGE E. COLE®
LEGAL FORMS

Handwritten signature

well son

SEALING FORM



DuPage County Health Department, Environmental Health Services
111 N. County Farm Road, Wheaton, IL 60187

11410-LI-2004

This form shall be submitted to this Department not more than 30 days after a well is sealed. Wells shall be sealed in accordance with sealing requirements in the DuPage County Private Water Supply Ordinance.

- 1. Ownership 400 Cliff Ct Lisle
- 2. Well location 400 Cliff Court Lisle
 Name 400 Cliff Court Address Lisle City
 Parcel # 08-14-402-025
SE Quarter of the NW Quarter of the SE Quarter of
 Section 14 Township 38 N, Range 10 E of the 3rd principal meridian.
- 3. Year drilled _____ 4. Permit # (date if known) _____
 (Leave blank if unknown) (Leave blank if unknown)
- 5. Type of well: Drilled , Bored _____, Driven _____, Other _____
- 6. Total depth 165, diameter (inches) 5"
- 7. Well clear of obstructions? Yes , No _____
 If no, record depth and type of obstruction. _____

- 8. Details of well sealing:
 Filled with Bentonite Chips from 0 to 165' ft.
 Sealing material _____ from _____ to _____ ft.
 Filled with _____ from _____ to _____ ft.
 Sealing material _____ from _____ to _____ ft.
 Filled with _____ from _____ to _____ ft.
 Sealing material _____ from _____ to _____ ft.

- 9. Casing record:
 Upper 2 feet of casing removed? Yes , No _____. If no, record actual depth and reason for variation. _____
 If well casing consists of brick, stone, or other porous material, was casing removed 10 feet below surface?
 Yes _____, No _____

10. Date well was sealed 8 / 11 / 2004
 Month Day Year

- 11. Licensed water well driller or other person approved by the Department performing well sealing:
Draine State Water Systems, Inc
Steven Shberg
 Name Steven Shberg Signature
1620 W. Meadow Ln 102-002730
 Address Complete License Number
Lombard IL 60148
 City State / Zip
630/261-1500

*Show well location on reverse side.

Ann G. Gurnea



DuPage County Health Department

111 North County Farm Road

Wheaton, IL 60187-3988

Telephone: (630) 682-7400

www.dupagehealth.org

REQUEST FOR PUBLIC RECORDS

Date: 1-12-05

TO: Pat Flaherty
FOIA OFFICER

DuPage County Health Department
DEPARTMENT/AGENCY

111 North County Farm Road
Wheaton, IL 60187
ADDRESS

630-682-7979 Ext. 7555
PHONE NUMBER

630-221-6811
FAX NUMBER

FROM:

Collins Law Firm
Ruta Norlus
NAME

1770 N. Park St., Rm. 200
ADDRESS

Naperville, IL 60563
CITY, STATE, ZIP

(630) 527-1595
PHONE NUMBER

DESCRIPTION OF REQUESTED RECORD(S):

Well Seal Form # 11410-LI-2004
400 Cliff Court
Lytle, IL 60532

Please indicate if you wish to inspect the above captioned records or wish a copy of them:

Inspection

Copy*

Both*

*Copied documents available upon receipt of payment for copying costs in the amount of \$1.00 per page.

FOR OFFICE USE ONLY:

Date Received

Date Response Due

Notations regarding oral communications or other items:

Illinois Department of
**Public
Health**

George H. Ryan, Governor • John R. Lumpkin, M.D., M.P.H., Director

525-535 West Jefferson Street • Springfield, Illinois 62761-0001

#910260001H

February 26, 2001

DANIEL L. SACCO
400 CLIFF COURT
Lisle, IL 60532

Dear Resident:

The Illinois Department of Public Health (IDPH) has received the laboratory results of the well water sample collected at your home on 01/31/2001 by the Illinois Environmental Protection Agency and analyzed by Prairie Analytical Systems, Inc. Your water was analyzed for 34 volatile organic chemicals (VOCs). Our evaluation of the data is based on the assumption that the samples were collected and handled properly and that appropriate analytical techniques were used.

The results of the analysis of your water sample showed the following VOCs:

Chemical	Level Detected (in ppb)	Maximum Contaminant Level (in ppb)
trichloroethene	1.12	5

ppb -- parts per billion, or microgram of chemical per liter of water

maximum contaminant level -- enforceable level established by the U.S. Environmental Protection Agency for public water supplies to reduce the chances of adverse health effects from contaminated drinking water

Although VOCs were detected in your water, exposure to this level would not be expected to cause adverse health effects. Based on these results, IDPH does not recommend any changes in your current water use patterns at this time. We recommend that your well water be tested quarterly for VOCs. If you wish to reduce your exposure to VOCs you may consider using bottled water for drinking or cooking purposes.

If you have any questions or require any additional information, feel free to contact us at 217-782-5830.

Sincerely,



Ken Runkle
Toxicology Section

cc: Stan Komperda, IEPA
IDPH West Chicago Regional Office
DuPage County Health Department

	IEPA Sample No.: G-316
IEPA SDG. No.: Not Available	SITE NAME: Lisle Residential Wells
Lab Name: Prairie Analytical Systems, Inc.	Batch No.: ICL-106
Matrix: Aqueous (DW)	Lab Sample ID: CR0102010092
Analytical Method No.: 524.2 Rev. 4.0	Lab File ID: 020701\0701007
Extraction Procedure No.: 524.2 Rev. 4.0	Date Received: 01 Feb 01
% Solids: 0.0	Date Extracted: 07 Feb 01
Dilution Factor: 1	Date Analyzed: 07 Feb 01

Analyte	Conc.	Q	C
Chloromethane	µg/L	0.50U	
Bromomethane	µg/L	0.50U	
Vinyl Chloride	µg/L	0.50U	
Chloroethane	µg/L	0.50U	
Methylene Chloride	µg/L	0.50U	
Acetone	µg/L	0.50U	
Carbon Disulfide	µg/L	0.50U	
1,1-Dichloroethene	µg/L	0.50U	
1,1-Dichloroethane	µg/L	0.50U	
1,2-Dichloroethene (total)	µg/L	0.50U	
Chloroform	µg/L	0.50U	
1,2-Dichloroethane	µg/L	0.50U	
2-Butanone	µg/L	0.50U	
1,1,1-Trichloroethane	µg/L	0.50U	
Carbon Tetrachloride	µg/L	0.50U	
Bromodichloromethane	µg/L	0.50U	
1,2-Dichloropropane	µg/L	0.50U	
cis-1,3-Dichloropropene	µg/L	0.50U	
Trichloroethene	µg/L		1.12
Dibromochloromethane	µg/L	0.50U	
1,1,2-Trichloroethane	µg/L	0.50U	
Benzene	µg/L	0.50U	
trans-1,3-Dichloropropene	µg/L	0.50U	
Bromoform	µg/L	0.50U	
4-Methyl-2-pentanone	µg/L	0.50U	
2-Hexanone	µg/L	0.50U	
Tetrachloroethene	µg/L	0.50U	
1,1,2,2-Tetracloroethane	µg/L	0.50U	
Toluene	µg/L	0.50U	
Chlorobenzene	µg/L	0.50U	
Ethylbenzene	µg/L	0.50U	
Styrene	µg/L	0.50U	
Xylenes (total)	µg/L	0.50U	
MTBE	µg/L	0.50U	

11 of 2

NORTHWESTERN MEMORIAL HOSPITAL
DISCHARGE SUMMARY

NAME: Sacco, Daniel
PHYSICIAN: Steven Campbell, MD
PAT. TYPE: 1
ADMIT DATE: 09/07/2000

HOSPITAL #: 00010191-9750
BILLING #: 000044100170
PATIENT LOC: 611W11C01
DISCH DATE: 09/16/2000

DISCHARGE DIAGNOSIS: Renal cell carcinoma status post right partial nephrectomy.

HISTORY OF PRESENT ILLNESS: The patient is a 52-year-old man with a history of left radical nephrectomy at age 28. He remained with no evidence of disease for many years. Patient recently developed abdominal pain and subsequent CT scan was positive for a right lower pole kidney mass approximately 4 cm in size. PAST MEDICAL HISTORY: His past medical history includes mild sleep apnea and bilateral knee surgery. MEDICATIONS: Patient's medications on admission include a bowel regimen including Prevacid, Zantac, and Metamucil. ALLERGIES: Patient is allergic to cephalosporins and Novocain.

HOSPITAL COURSE: On September 7, 2000, the patient underwent a right partial nephrectomy. Patient tolerated the procedure well and there were no complications. Postoperatively, the patient spent approximately 4 days in the surgical intensive care unit, where his volume status, urine output, and electrolytes were closely monitored. Postoperatively, the patient did have a significant rise in his serum creatinine levels. He was followed by the renal service, and gradually the patient's urine output began to increase without the assistance of diuretics. He gradually began to tolerate a full p.o. diet and was ambulating without assistance. The patient's serum creatinine peaked to 7.6 and after transfer to the floor, where the patient remained afebrile with stable vital signs and making adequate amounts of urine, the patient's serum creatinine gradually decreased to 4.1 the day of discharge. While on the floor, the patient did complain of hallucinations and night terrors while sleeping. These gradually improved without intervention. By postop day #9, the patient was in stable condition and discharged home with the following instructions.


DISCHARGE INSTRUCTIONS: He was allowed to shower but not soak in a tub. He was discharged home on Vicodin 1-2 tabs p.o. q.4-6h. p.r.n. and Colace 100 mg p.o. b.i.d. Patient was instructed not to lift anything greater than 10 pounds for 6 weeks and not to drive an automobile until pain free and not taking pain medicine. The patient was instructed to eat a renal diet, which included a low-protein, low-potassium diet. He was instructed to return to the hospital for a temperature greater than 101.0 degrees, severe pain, nausea, vomiting,

CHART COPY

or any increasing redness, drainage, or discharge from his incision. The patient was discharged home with his Jackson-Pratt drain and will follow up with Dr. Campbell within 1 week of discharge to have his JP drain removed in the office.

Amc D: 09/17/2000 T: 09/18/2000 1:55 P

DOC#: 179306
JOB#: 019694

 9/21/00

Steven Campbell, MD
Dictated by: Daniel Williams, MD

cc: Steven Campbell, MD

CHART COPY

NAME: SACCO, DANIEL (52Y M)
MRN : 101919759
ACCT: 44100170
SSN : 223-42-6683
LOC : F0720-1

LAB NO: 800-19228
DATE: 09/07/2000
ATTENDING: CAMPBELL, STEVEN C.

SPECIAL STUDIES: FROZEN SECTION
DOCUMENT CREATED: 09/08/2000 0934

PHOTOGRAPHS:

FINAL DIAGNOSIS

- A. PERINEPHRIC FAT AND 11TH RIB, RESECTION;
- SEGMENT OF RIB (GROSS EXAMINATION ONLY).
- PORTION OF ADIPOSE TISSUE, NEGATIVE FOR CARCINOMA. *PT INK MLO*
- B. PARTIAL KIDNEY, RIGHT SIDE, PARTIAL NEPHRECTOMY;
- RENAL CELL CARCINOMA, CLEAR CELL TYPE, GRADE II, MEASURING
2.5 X 2.4 X 2.4 CM.
- INKED PARENCHYMAL MARGIN OF RESECTION FREE OF TUMOR.
- RENAL CAPSULE FOCALLY PENETRATED BUT NOT PERFORATED.
- PERINEPHRIC FAT, NEGATIVE FOR TUMOR.
- C. ANTERIOR SURFACE OF KIDNEY, BIOPSY;
- PORTION OF RENAL PARENCHYMA, NEGATIVE FOR CARCINOMA.
- D. POSTERIOR SURFACE OVER TUMOR, KIDNEY, BIOPSY;
- PORTION OF RENAL PARENCHYMA, NEGATIVE FOR CARCINOMA.

RENAL CANCER STAGING SUMMARY

TUMOR TYPE.....>RENAL CELL CARCINOMA, CLEAR CELL TYPE
GRADE*.....>2
SIZE.....>2.5 X 2.4 X 2.4 CM
TUMOR INVASION
RENAL CAPSULE.....>FREE
GEROTA'S FASCIA.....>FREE
OTHER (BEYOND FASCIA).....>N/A
RENAL VEIN INVASION.....>N/A
VENA CAVA INVOLVEMENT.....>N/A
MARGINS
INTRAPARENCHYMAL.....>FREE
PERIRENAL SOFT TISSUE.....>FREE
VASCULAR.....>N/A
LYMPH NODES
TOTAL HILAR.....>NONE
NUMBER POSITIVE.....>N/A
TOTAL PERIAORTIC.....>NONE
NUMBER POSITIVE.....>N/A
TUMOR BANK.....>NO

REPORT PRINTED: 09/08/2000 1633

(continued on next page)

800-13220 BRCCO, DANIEL (CONTINUED)

TUMOR VACCINE.....>NO

*Fuhrman's nuclear grading system is used to grade renal cell carcinoma.

MP D&T: 9/8/00

PATHOLOGIST

PACITA KEH, M.D.

CLINICAL HISTORY

The patient is a 52-year-old male with a clinical diagnosis of renal mass right, undergoing right nephrectomy.

GROSS DESCRIPTION

- A. Received in formalin labeled with the patient's name and designated on the requisition as "perinephric fat and 11th rib" is a 12 x 7 x 2 cm triangular yellow fibroadipose fragment and a 8.1 x 1.1 x 0.4 cm segment of unremarkable rib. The rib is examined grossly only. The remaining tissue consist of fat with hemorrhage and does not contain gross lesions. Representative sections are submitted in 2 cassettes.
- B. Received fresh labeled with the patient's name and designated on the requisition as "right partial kidney" is a 109 gram 6 x 5 x 5 cm partial nephrectomy specimen which is oriented by Dr. Campbell. The specimen is bisected to reveal a 2.5 x 2.4 x 2.4 cm tan-yellow and red heterogenous parenchymal based mass which extends to the capsule but does not invade through it. The capsular margin is inked black and the en face surgical margin is inked green. The parenchymal margin contains a 0.1 to 0.3 cm rim of uninvolved renal tissue and the margin is grossly said to be free by Dr. Pins. A 1.5 cm simple cyst is directly adjacent to the lesion. Representative sections are submitted as follows:
- 1-3 - en face margin
 - 4-5 - tumor at capsular margin
 - 6-7 - representative sections of tumor
 - 8 - cyst
 - 9 - adjacent renal parenchyma
- C. Received fresh for frozen section labeled with the patient's name and designated on the requisition as "anterior surface shaved margin" are two tan renal tissue fragments measuring 1.0 x 0.5 x 0.5 cm in aggregate. The entire specimen is frozen and frozen diagnosis by

REPORT PRINTED: 09/08/2000 1633

(continued on next page)